

Microneedling: A Comprehensive Review

ANGELA HOU, BS, BA, BRANDON COHEN, MD, ADELE HAIMOVIC, MD, AND
NADA ELBULUK, MD, MSc*

BACKGROUND Microneedling is a minimally invasive procedure that uses fine needles to puncture the epidermis. The microwounds created stimulate the release of growth factors and induce collagen production. The epidermis remains relatively intact, therefore helping to limit adverse events. The indications for microneedling therapy have grown significantly, and it is becoming a more widely used treatment in dermatology.

OBJECTIVE A comprehensive review of microneedling in human subjects and its applications in dermatology.

METHODS AND MATERIALS A search was performed using PubMed/MEDLINE and Science Direct databases. Search terms included "microneedling," "needling," and "percutaneous collagen induction." All available studies involving human subjects were included in the discussion, with priority given to prospective, randomized trials.

RESULTS Studies demonstrate microneedling efficacy and safety for the treatment of scars, acne, melasma, photodamage, skin rejuvenation, hyperhidrosis and alopecia and for facilitation of transdermal drug delivery. While permanent adverse events are uncommon, transient erythema and postinflammatory hyperpigmentation are more commonly reported.

CONCLUSION Microneedling appears to be an overall effective and safe therapeutic option for numerous dermatologic conditions. Larger and more randomized controlled trials are needed to provide greater data on the use of microneedling for different dermatologic conditions in different skin types.

The authors have indicated no significant interest with commercial supporters.

Microneedling, also known as percutaneous collagen induction (PCI), is a minimally invasive technology used to treat numerous dermatologic conditions.¹ In 1995, Orentreich and Orentreich coined the term "subcision" to describe manual needling for the treatment of scars, while Camirand and Doucet used a tattoo gun to treat scars.^{2,3} These techniques used needles to disrupt dermal collagen that was tethering scars to trigger an inflammatory cascade, resulting in dermal remodeling and skin resurfacing.^{1,4} Employing these principles, Fernandes developed PCI therapy with a dermaroller mounted with tiny needles.¹

Modern microneedling devices contain multiple fine needles, typically 0.5 to 1.5 mm in length, located on a barrel and rolled onto the skin to create numerous punctures into the stratum corneum and the papillary dermis.⁵ These microwounds initiate the release of growth factors, triggering collagen and elastin formation in the dermis.⁶ Microneedling can also be used to augment transdermal drug delivery (TDD) through the creation of pores in the stratum corneum.⁷

The applications for microneedling have expanded over the past few decades to include the treatment of acne vulgaris, scars, facial rejuvenation, dyspigmentation, alopecia, hyperhidrosis, and TDD. This review provides

**All authors are affiliated with the Ronald O. Perelman Department of Dermatology, New York University School of Medicine, New York, New York*

© 2016 by the American Society for Dermatologic Surgery, Inc. Published by Wolters Kluwer Health, Inc. All rights reserved.
ISSN: 1076-0512 • Dermatol Surg 2017;43:321-339 • DOI: 10.1097/DSS.0000000000000924

TABLE 1. Summary of Microneedling Studies

Author	Year	Patient No., n	Level of Evidence*	Study Design	Indication
Acne scars					
Alam and colleagues ⁹	2014	20	1C	Prospective split-face trial	Atrophic acne scars
Chandrashekar and colleagues ²⁴	2014	31	4	Retrospective	Moderate-severe facial atrophic acne scars
Chawla and colleagues ²²	2014	30	1C	Prospective trial of microneedling + PRP or topical VC	Atrophic facial acne scars
Cho and colleagues ²⁶	2012	30	2C	Uncontrolled, prospective study	Acne scars and large facial pores
Dogra and colleagues ¹²	2104	36	2C	Uncontrolled, prospective study	Atrophic acne scars
Fabbrocini and colleagues ¹⁰	2014	60	1C	Prospective, nonblinded study comparing outcomes in 3 groups: FST I-II, FST III-V, or FST VI	Atrophic acne scars
Fabbrocini and colleagues ²⁰	2011	12	1C	Split-face prospective trial of microneedling ± PRP	Atrophic acne scars
Fabbrocini and colleagues ¹¹	2009	32	2c	Pilot study (no control group)	Rolling acne scars
Gadkari and colleagues ¹⁵	2014	37	1C	Prospective split-face trial of subcision with microneedling or cryorolling	Atrophic acne scars
Garg and colleagues ¹⁷	2014	50	2C	Uncontrolled, prospective study of the dermaroller and 15% TCA peels	Atrophic acne scars
Hassan and colleagues ¹⁴	2015	70	1C	RCT of microneedling alone or microneedling plus subcision	Atrophic acne scars
Leheta and colleagues ¹⁸	2014	24	1C	RCT of microneedling and 20% TCA or single skin peel with 60% phenol	Atrophic acne scars
Leheta and colleagues ¹⁹	2014	39	1C	RCT of microneedling with 20% TCA (Group 1), fractional thermolysis (Group 2), or a combination of the 2 modalities (Group 3).	Atrophic acne scars
Leheta and colleagues ¹⁶	2011	30	1C	RCT of microneedling vs 20% TCA	Atrophic acne scars
Mohammed and colleagues ²⁷	2013	60	1C	RCT of pinpoint CO ₂ laser with or without needling	Moderate-severe ice pick scars
Nofal and colleagues ²¹	2014	45	1C	RCT of intradermal PRP, topical TCA 100%, or microneedling with topical PRP	Atrophic acne scars

TABLE 1. (Continued)

Author	Year	Patient No., n	Level of Evidence*	Study Design	Indication
Sharad and colleagues ²³	2011	60	1C	Prospective study of microneedling alone (Group 1) or microneedling + 35% GA peels (Group 2)	Atrophic acne scars
Vejjabhinanta and colleagues ²⁵	2014	26	2C	Uncontrolled, prospective study	Atrophic acne scars
Other scars					
Aust and colleagues ⁴	2008	480	4	Retrospective	Fine wrinkles (Group 1), acne or burn scars (Group II), and lax skin/stretch marks (Group III)
Aust and colleagues ³⁷	2010	22	2C	Uncontrolled, prospective study	Striae distensae
Aust and colleagues ³⁴	2010	16	2C	Uncontrolled, prospective study of microneedling with topical VAC	Burn scars
Cho and colleagues ³⁸	2008	1	4	Case report	Burn scar
Costa and colleagues ³³	2014	1	4	Case report	Varicella scars
Majid and colleagues ³²	2009	37	2C	Uncontrolled, prospective study	Atrophic scars of various etiology
Park and colleagues ³⁵	2012	16	2C	Uncontrolled, prospective study	Striae distensae
Schwarz and Laaff ³¹	2011	11	2C	Uncontrolled, prospective study	Acne scars and post-traumatic scars on the face, trunk, and lower extremities.
Melasma/Melanosis					
Budamakuntla and colleagues ³⁹	2013	60	1C	RCT using TA microinjections with or without microneedling	Moderate-severe melasma
Fabbrocini and colleagues ⁴⁰	2011	20	1C	Split-face trial of depigmentation serum containing rucinol and sophora-alpha with or without microneedling	Melasma
Sahni and colleagues ⁴¹	2013	1	4	Case report	Periorbital melanosis
Active acne					
Kim and colleagues ²⁹	2014	25	2C	Uncontrolled, prospective study	Moderate to severe acne vulgaris
Lee and colleagues ³⁰	2013	20	2C	Uncontrolled, prospective study	Acne Vulgaris
Lee and colleagues ²⁸	2012	18	4	Retrospective	Moderate to severe acne vulgaris
Skin rejuvenation					
Fabbrocini and colleagues ⁴⁶	2011	8	2C	Uncontrolled, prospective study	Signs of neck aging
Fabbrocini and colleagues ⁴⁵	2012	10	2C	Uncontrolled, prospective study	Upper lip wrinkles
Seo and colleagues ⁴⁷	2013	15	1C	Prospective split-face trial of MFR ± "stem cell medium"	Facial rejuvenation

TABLE 1. (Continued)

<i>Author</i>	<i>Year</i>	<i>Patient No., n</i>	<i>Level of Evidence*</i>	<i>Study Design</i>	<i>Indication</i>
Hyperhidrosis Kim and colleagues ⁴⁸	2013	20	2C	Uncontrolled, prospective study	Primary axillary hyperhidrosis
Photodamage/AKs Bencini and colleagues ⁴⁴	2012	12	2C	Uncontrolled, prospective study of microneedling with topical MAL-based PDT	Actinic keratoses
Clementoni and colleagues ⁴²	2010	21	2C	Uncontrolled, prospective study of microneedling before PDT with ALA and irradiation with 630 nm red light and broadband-pulsed	Facial photoaging
Torezan and colleagues ⁴³	2013	10	1C	Prospective trial comparing PDT with methyl aminolevulinate (MAL) with either pre-treatment curettage or microneedling	AK and photodamage
Androgenic alopecia Dhurat and colleagues ⁴⁹	2013	100	1C	Prospective randomized trial of microneedling with 5% minoxidil lotion or minoxidil alone	Androgenic alopecia
Drug delivery Fabbrocini and colleagues ⁵⁵	2014	15	1C	Prospective, controlled trial examining delivery of topical anesthetics with or without microneedling	Transdermal drug delivery
<i>Author</i>	<i>Device</i>	<i>Treatment No. (Interval)</i>	<i>Scoring Method</i>	<i>Primary Outcome</i>	<i>Adverse Effects (%)</i>
Acne scars Alam and colleagues ⁹	MTS roller CR10 or CR20	3 (2 wks)	Goodman and Baron's acne scar grading system	Significant improved mean scar scores by 3.4 points ($p = 0.03$) in treatment group vs 0.4 ($p > 0.99$) in control group	None reported
Chandrashekar and colleagues ²⁴	MRF. (power: 25–40 W, depth: 1.5–3.5 mm)	4 (6 wks)	Goodman and Baron's acne scar grading system	81% of patients improved by 2 grades, 19% of patients improved by 1 grade	Transient erythema and edema (100%), PIH (16%), tram-trak scarring (6%)

TABLE 1. (Continued)

Author	Device	Treatment No. (Interval)	Scoring Method	Primary Outcome	Adverse Effects (%)
Chawla and colleagues ²²	Dermaroller MS4	4 (4 wks)	Goodman and Baron's acne scar grading system	"Excellent" response in 18.5% of patients treated with microneedling + PRP, vs 7% in those treated with microneedling + vitamin C	PIH (3.3%)
Cho and colleagues ²⁶	MRF (49 needles, length 1.5 mm, 500 W)	2 (6 wks)	Photographic grading (1–4) by 2 blinded dermatologists	73% demonstrated improvement of acne scar grade (21 patients improved by 1 grade, one patient improved by 2 grades)	Erythema (100%), folliculitis (6.7%)
Dogra and colleagues ¹²	Dermaroller MS4	5 (4 wks)	Photograph assessment on a quartile scale	50%–75% average improvement in the "majority" of subjects	PIH (17%), tram-trak scarring (7%)
Fabbrocini and colleagues ¹⁰	Dermaroller MS4	3 (4 wks)	Global aesthetic improvement scale	Significant reduction in the depth of scars and average reduction of 31% in skin texture irregularity	Post-treatment erythema (majority of FST I–II subjects)
Fabbrocini and colleagues ²⁰	Microneedling device (96 needles, length: 1.5 mm, 10–14 passes)	2 (8 wks)	Photograph assessment on a subjective 0–10 scale.	Baseline severity score was 7.5 in both groups, which improved to 4.9 and 4.0 in the microneedling alone and combined groups, respectively.	None reported
Fabbrocini and colleagues ¹¹	Microneedles with 1.5–2 mm depth, 250–300 pricks per cm ²	2 (8 wks)	Photograph assessment on a 0–10 severity scale. Silicon rubber model of scars in 5 patients	Improvement of rolling scars in all patients and 25% average reduction in skin irregularity	None reported
Gadkari and colleagues ¹⁵	Dermaroller (192 needles, length 2.5 mm)	3 (4 wks)	Goodman and Baron's acne scar grading system	Mean improvement of 57% with subcision and cryoroller, compared to 40% improvement in those who received subcision and microneedling ($p < 0.5$)	Microneedling group: transient erythema (100%)

TABLE 1. (Continued)

<i>Author</i>	<i>Device</i>	<i>Treatment No. (Interval)</i>	<i>Scoring Method</i>	<i>Primary Outcome</i>	<i>Adverse Effects (%)</i>
Garg and colleagues ¹⁷	Dermaroller MS4	3 (2 wks)	Goodman and Baron qualitative grading scale	63% with Grade 4 scars improved to Grade 2, 38% improved to Grade 3. 23% of Grade 3 scars had full resolution, and 68% improved to Grade 2. 100% with Grade 2 scars had full resolution	Cryorolling group: PIH (17%) Postprocedure erythema and edema ("majority" of patients), PIH (6%), and cervical lymphadenopathy (2%)
Hassan and colleagues ¹⁴	Dermaroller (Horst, Liebel, Germany). 20 G cataract blade for subcision	3 (4 wks)	Photograph assessment by investigators on a quartile scarring scheme	Efficacy (at least 25% improvement) was demonstrated in 77% of patients who received microneedling alone, compared to 100% of patients receiving microneedling and subcision	Post-treatment erythema, edema (100%)
Leheta and colleagues ¹⁸	Dermaroller (Horst)	4 (6 wks)	Live assessment by a blinded dermatologist based on a weighted quartile grading scale	The microneedling group improved by a mean of 69% compared to 75% in the deep skin-peel group ($p > 0.05$).	Phenol peel: Persistent erythema (20%) Microneedling group: Procedural pain, transient erythema/edema (100%)
Leheta and colleagues ¹⁹	Dermaroller (Horst). Fractional 1,540 nm nonablative laser.	6 (4 wks)	Blinded photograph assessment on a quartile scale	Mean improvement of 60% in Group 1, 62% in Group 2, and 78% in Group 3. Statistically greater improvement of rolling type scars in Groups 1 and 3 and boxcar type scars in Groups 2 and 3.	Transient edema/erythema (unreported), desquamation after peeling (unreported).

TABLE 1. (Continued)

<i>Author</i>	<i>Device</i>	<i>Treatment No. (Interval)</i>	<i>Scoring Method</i>	<i>Primary Outcome</i>	<i>Adverse Effects (%)</i>
Leheta and colleagues ¹⁶	Dermaroller (Horst)	4 (4 wks)	Blinded photograph assessment on a quartile scale	All patients experienced improvement, with no statistically significant difference in mean improvement between groups (68.3% vs 75.3%, $p = 0.47$)	Erythema and edema (unreported), acne exacerbation (13%)
Mohammed and colleagues ²⁷	Needling with a 26-G needle. Ablative carbon dioxide laser used to deliver pinpoint irradiation	5 (2–3 wks)	Goodman and Baron’s acne scar grading system	There was a statistically significant improvement after treatment in both groups ($p < 0.05$) with no statistical difference between the 2 treatment groups.	None reported
Nofal and colleagues ²¹	Dermaroller MT20	3 (2 wks)	Goodman and Baron’s acne scar grading system	All groups showed statistically significant improvement in scar severity ($p < 0.001$), with no significant difference between groups.	None reported
Sharad and colleagues ²³	Dermaroller MS4	5 (6 wks)	Scale for clinical evaluation of acne scars (Echelle d’Evaluation clinique des Cicatrices d’acné)	Group 1 demonstrated 31% mean improvement, compared to 62% improvement in Group 2	Transient bruising and edema (“majority” of patients), milia (7%) and PIH (10%)
Vejjabhinanta and colleagues ²⁵	INTRAcel Device	3 (4 wks)	Clinical comparison of photographs by 2 blinded evaluators	Improvement was graded as “slightly improved” in 33%, “fair” in 37%, “good” in 23%, “excellent” 8%	Skin scabbing (46%), transient PIH (4%)
Other scars					
Aust and colleagues ⁴	Medical, roll-CIT (Vivida, Cape Town, South Africa)	1–4 treatments (variable)	Vancouver scar scale score (VSS)	Mean score of 7.5 points at baseline improved to 4.8 points	HSV reactivation (7%)
Aust and colleagues ³⁷	Percutaneous collagen induction, (device unspecified)	1	Subjective clinical assessment and biopsy	Improvement in skin texture and tightening. Increase in collagen and elastin content.	None reported

TABLE 1. (Continued)

<i>Author</i>	<i>Device</i>	<i>Treatment No. (Interval)</i>	<i>Scoring Method</i>	<i>Primary Outcome</i>	<i>Adverse Effects (%)</i>
Aust and colleagues ³⁴	Medical, roll-CIT (Vivida)	1–4 treatments (variable)	Vancouver scar scale score and the patient and observer scar assessment scale	Patients reported 80% mean improvement in scar appearance.	None reported
Cho and colleagues ³⁸	DermaRoller (Horst). Ablative carbon dioxide laser	5 (4 wks)	Subjective assessment of photographs	Reduction of contracture and improvement in texture	None reported
Costa and colleagues ³³	DermaRoller MS4	3 (4 wks)	Subjective assessment of photographs	Significant improvement in the appearance of scars	Postprocedure erythema (unreported)
Majid and colleagues ³²	DermaRoller MS4	3–4 (4–8 wks)	Goodman and Baron's system	94% had a reduction in severity by one or 2 grades.	Transient erythema ("majority"), PIH (3%)
Park and colleagues ³⁵	DTS roller	3 (4 wks)	Photos were assessed by 2 independent dermatologists using a quartile grading system	7 patients reported 51%–100% improvement, with the remaining 9 reporting 1%–50% improvement.	Transient erythema and pruritus, (unreported)
Schwarz and Laaff ³¹	DermaRoller (Horst)	1	Histologic examination	Up to ×2 increase in elastic fiber content in 70% of patients.	None reported
Melasma/ Melanosis Budamakuntla and colleagues ³⁹	DermaRoller MS4	3 (4 wks)	MASI score	38% average improvement in MASI score with TA alone, vs 44% improvement in those who received TA plus microneedling	None reported
Fabbrocini and colleagues ⁴⁰	DermaRoller CIT 8 in office and DermaRoller C8 at home	1 office treatment, 60 home treatments (daily)	MASI score	Mean MASI score improvement of 10.1 points after combined treatment vs 7.1 point improvement with depigmenting serum alone.	Transient erythema and edema (100%)
Sahni and colleagues ⁴¹	DermaFrac (Genesis Biosystems, Lewisville, TX)	12 (2 wks)	Physician global assessment	75%–90% improvement after 12 treatment sessions	None reported

TABLE 1. (Continued)

<i>Author</i>	<i>Device</i>	<i>Treatment No. (Interval)</i>	<i>Scoring Method</i>	<i>Primary Outcome</i>	<i>Adverse Effects (%)</i>
Active acne					
Kim and colleagues ²⁹	INTRAcel device, (Jeisys Medical, Seoul, South Korea)	3 (4 wks)	Photograph assessment of lesion number and Sebumeter (C-K Electronics, Cologne, Germany for sebum excretion measures	Active lesions counted decreased by an average of 76% and sebum content was reduced by 37%	Bleeding (20%), edema/erythema (32%), and crusting (24%)
Lee and colleagues ³⁰	Infini device (Lutronic, Goyang, Korea)	1	Physician’s global assessment. measurement of casual sebum level (CSL) and sebum excretion rate (SER)	Reduction of sebum excretion by 70%–80%. Acne appearance showed transient improvement but returned to baseline scores by 8 wks post-treatment	Postprocedure bleeding, erythema, and edema (“common”)
Lee and colleagues ²⁸	MFR (depth: 3 mm, intensity: 7; and RF conduct time: 100 off-500 on-100 off ms)	2 (4 wks)	Photograph assessment on a quartile scaring scheme	Mean improvement in inflammatory lesion number by 2.6 points and reduction in lesion severity by 2.4 points	Erythema/edema (“majority”)
Skin rejuvenation					
Fabbrocini and colleagues ⁴⁶	Dermaroller MF8	2 (8 wks)	Wrinkle Severity Rating Scale (WSRS), Global Aesthetic Improvement Scale (GAIS), skin replicas, and ultrasound exam	88% of patients improved based on WSRS and GAIS. Skin replicas demonstrated an average reduction in skin irregularity of 29%. Sonography showed 24% reduction in rhytide depth and 0.45 mm average increase in skin thickness.	None reported
Fabbrocini and colleagues ⁴⁵	Microneedling device (96 needles, length: 1.5 mm, 10–14 passes)	2 (8 wks)	Wrinkle Severity Rating Scale and Microsurface model analysis	Mean 2.3 times reduction in wrinkle severity, 33% reduction in skin irregularly	Transient postprocedure erythema and edema (100%)

TABLE 1. (Continued)

<i>Author</i>	<i>Device</i>	<i>Treatment No. (Interval)</i>	<i>Scoring Method</i>	<i>Primary Outcome</i>	<i>Adverse Effects (%)</i>
Seo and colleagues ⁴⁷	5 noninsulated microneedle electrode pairs per 10 mm ²	3 (4 wks)	Physician's global assessment on quartile scale	Significant benefit in skin roughness associated with stem cell medium compared to MRF alone (2.20 vs 2.06 mean improvement, $p < 0.05$).	Mild erythema (100%)
Hyperhidrosis Kim and colleagues ⁴⁸	Infini device	2 (4 wks)	Hyperhidrosis Disease Severity Scale (HDSS) and Starch Iodine Test	Starch iodine test demonstrated significant reductions after treatment in 95% of patients. Mean HDSS score decreased from 2.2 to 1.8 points. Decreases in the number and size of eccrine and apocrine glands were revealed	Postprocedure edema ("most patients") PIH (unreported), compensatory hyperhidrosis (10%)
Photodamage/AKs Bencini and colleagues ⁴⁴	Dermaroller MS4	3 (2 wks)	Clinical assessment on 0–3 point scale.	After the third treatment, all lesions demonstrated complete resolution. No novel lesions were detected by 4-mo follow-up and 83% of patients remained free of relapse 9 mo after final treatment	None reported
Clementoni and colleagues ⁴²	Microneedling device (0.1 2 mm width and 0.3 mm length)	1	Mean global photoaging score	Photoaging score decreased from 3.57 at baseline to 2.24 after 3 mo and 2.05 after 6 mo ($p < 0.05$). Statistically significant reductions in the appearance of fine lines, sallowness, and roughness	Transient crusting ("majority of patients). Erythema and edema (71%)

TABLE 1. (Continued)

<i>Author</i>	<i>Device</i>	<i>Treatment No. (Interval)</i>	<i>Scoring Method</i>	<i>Primary Outcome</i>	<i>Adverse Effects (%)</i>
Torezan and colleagues ⁴³	Dermaroller MS4	1	Clinical assessment of photographs by 2 independent dermatologists.	AK clearance was 88.3%, without significant differences in clearance rates between groups. Patients treated with microneedling also demonstrated significant improvements in coarse wrinkles and erythema	Erythema, edema, and crusting (“common”) Bacterial superinfection (10%)
Androgenic alopecia Dhurat and colleagues ⁴⁹	Dermaroller MS4	12 (1 wk)	Hair count assessed by macrophotographs	Hair count was significantly greater in patients treated with microneedling and minoxidil compared to with minoxidil alone (91.4 vs 22.2 mean count).	None reported
Drug delivery Fabbrocini and colleagues ⁵⁵	Dermaroller MS4	1	Visual analog scale (VAS) pain scores	Microneedling prior to the topical anesthetic resulted in a significantly reduced VAS pain score compared to anesthetic alone ($p < 0.05$)	None reported

*Level of Evidence: Based on recommendation from the Centre for Evidence-Based Medicine, Oxford (1a-5) (<http://www.cebm.net/oxford-centre-evidence-based-medicine-levels-evidence-march-2009/>).

ALA, Aminolevulinic acid; DermaFRAC, 0.25 mm tip cap, Pressure, 10 mmHg; Dermaroller C8, 196 needles, length 0.15 mm; Dermaroller CIT8, device 192 needles, Length, 0.5 mm, Width, 0.02 mm; Dermaroller MF8, 192 needles in 8 rows, length, 1.5 mm, diameter 0.25 mm; Dermaroller MS4 device, 192 needles, length 1.5 mm, width 0.25 mm; Dermaroller MT20, 192 needles, length 2 mm; Dermaroller, 200 needles, 0.5–2.5 mm; DTS Roller, 540 needles, length 1.5 mm; FST, Fitzpatrick Skin Type; GA, Glycolic Acid; HSV, Herpes Simplex Virus; Infini, 49 insulated microneedles spanning 10 mm² Depth, 0.5–3.5 mm, 1 MHz of radiofrequency current; INTRAcel device, 49 microneedles, Depth, 1.5 mm, Spot size, 10 mm; MAL, Methylaminolaevulinate; MASI, Melasma Area Severity Index; Medical Roll-CIT, 1 mm needles; MRF, Microneedling with Radiofrequency; MTS Roller CR10, 1 mm needles; MTS Roller CR20, 2 mm needles; PDT, Photodynamic therapy; PIH, Postinflammatory Hyperpigmentation; PRP, Platelet Rich Plasma; RCT, Randomized Controlled Trial; TA, Tranexamic acid; TCA, Trichloroacetic acid; VAC, Vitamin A and C; VC, Vitamin C.

a comprehensive overview of the available literature regarding the efficacy and safety of microneedling performed for dermatologic conditions in human subjects (Table 1). A search was performed using PubMed/MEDLINE and Science Direct databases. Search terms included “microneedling,” “needling,” and “percutaneous collagen induction.” All available studies involving human subjects were included in the discussion, with priority given to prospective, randomized trials (Figure 1).

Acne Scars

Microneedling has been most extensively studied for acne scar treatment. A recent review concluded that although studies analyzed were heterogeneous in design, there is moderate evidence supporting the use of PCI for acne scarring.⁸ Eight studies were examined microneedling as monotherapy for acne scars.^{8–16} One study was a split-face trial involving 20 patients with Fitzpatrick Skin Type (FST) I to V randomized to either microneedling with a topical anesthetic or topical anesthetic alone.⁹ Three sessions at 2-week intervals were performed, with 2 blinded dermatologists rating the photographs based on the Goodman and Baron grading system (GBGS). At the 6-month follow-up, there was a statistically significant decrease in the mean scores of the treatment group compared to the

control group (3.4 vs 0.4). No adverse effects (AE) were reported.⁹

A randomized controlled trial (RCT) divided 60 patients based on FST and assessed improvement using the Global Aesthetic Improvement Scale (GAIS), as well as computerized analysis of silicone replicas to quantify skin irregularity.¹⁰ After 3 treatment sessions, there was a significant reduction in the acne scar severity, as well as an average decrease in the degree of skin surface irregularity by 31% in all skin types.¹⁰ One case series examined 32 patients with rolling acne scars.¹¹ Each patient received 2 microneedling treatments and outcomes were evaluated by GBGS. The severity grade of rolling scars in all patients was significantly reduced ($p < 0.05$). Microrelief impressions of the scars cast as an objective measurement of the skin's topography showed a 25% decrease in irregularity and all samples showed decreased irregularity of skin texture. No AE were noted.¹¹

Another case series examined 36 patients (FST IV–V) after 5 microneedling sessions.¹² After 5 sessions, photograph assessment revealed a 50% to 75% average improvement. Adverse effects included pain and ecchymosis, and 5 patients dropped out of the study due to postinflammatory hyperpigmentation (PIH) and tram-trak scarring.¹² Tram-trak scarring, a unique AE

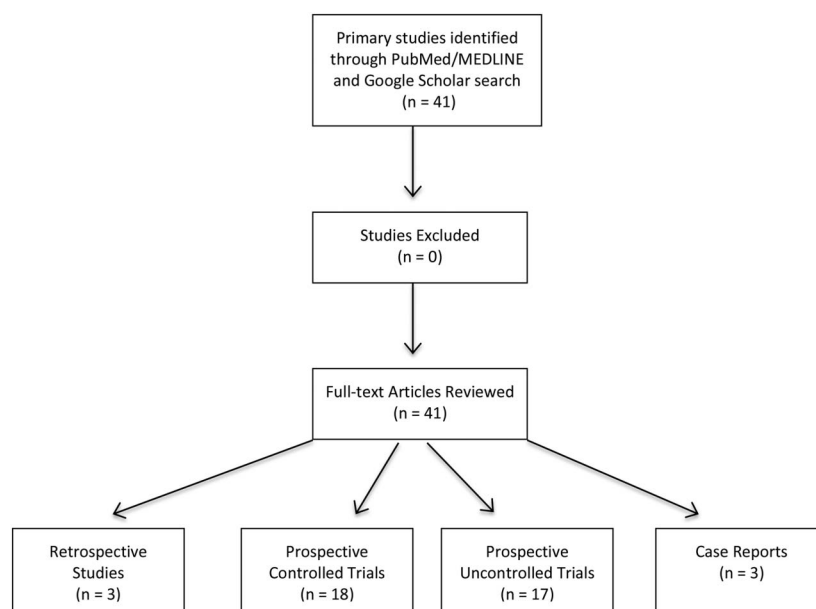


Figure 1. Flow diagram of study selection.

of microneedling, was also described in a 25-year-old female who underwent 2 sessions with a 2.0-mm-long microneedling device.¹³ The authors believed this was secondary to excess pressure applied while using the device and the larger and longer needles used.^{6,13}

Microneedling has been compared to other acne scar treatments, including subcision, cryorolling, and chemical reconstruction of skin scars (CROSS) with trichloroacetic acid (TCA). An RCT of 70 subjects compared patients receiving 3 sessions with either microneedling alone or microneedling with subcision with a 20-gauge cataract blade.¹⁴ Efficacy (>25% improvement) was demonstrated in 77% of patients who received microneedling alone compared to 100% of patients receiving microneedling and subcision. Adverse effects included transient erythema, edema, and mild scabbing for 2 to 3 days.¹⁴ Another split-face study compared subcision with either microneedling or cryorolling, which consists of dipping the device in liquid nitrogen prior to use.¹⁵ Thirty-seven patients were randomly assigned a treatment modality on either side of the face and assessed by a blinded observer using GBGS. Subcision with cryoroller was associated with a significantly higher mean improvement compared with subcision plus dermaroller (57% vs 40%). However, 16.7% of patients developed PIH after cryorolling, lasting a mean duration of 4 months. Microneedling treatment was associated only with transient erythema.¹⁵

Another RCT compared the efficacy of microneedling to TCA CROSS by randomly assigning 30 patients (FST II–IV) to 4 sessions of either treatment.¹⁶ Results were based on overall disease severity score and global response to treatment. All patients experienced acne scar improvement, with no significant difference between microneedling and TCA groups (68.3% vs 75.3%).¹⁶

Seven prospective studies have performed microneedling in conjunction with topical treatments, including vitamin C (VC), platelet-rich plasma (PRP), and chemical peels.^{17–23} One study evaluated 49 patients (FST III–V) using a regimen that alternated between microneedling and 15% TCA peel at 2-week intervals, with improvement based on GBGS.¹⁷ All 49 patients had at least one grade improvement in their

acne scarring. Ice pick scars were more treatment refractory compared to rolling, boxcar, and linear tunnel-type scars. All 11 patients with Grade 2 scarring demonstrated complete resolution. Three patients developed PIH, which subsided after 5 months of topical treatment.¹⁷ Another study randomly assigned 24 patients to treatment with microneedling and 20% TCA or deep skin peeling with 60% phenol.¹⁸ There was no statistical difference between the 2 groups on a quartile grading scale (69% vs 75%). Adverse effects included procedural pain, transient erythema, and swelling with peeling for 1 week.¹⁸ One study randomly assigned 39 patients to either skin needling with 20% TCA (Group I), fractional thermolysis (Group II), or a combination of the two (Group III).¹⁹ Assessment by a blinded dermatologist showed mean improvement of 60%, 62%, and 78%, respectively. The difference in degree of improvement was found to be significant between Groups I and III and Groups II and III, but no statistical difference between Groups I and II. Adverse effects included transient edema, erythema, and pain, along with desquamation 4 to 7 days after peels.¹⁹

Studies have also investigated microneedling with PRP. A study with 12 patients concluded that 2 sessions of microneedling with PRP was significantly more efficacious than microneedling alone although the study was limited by the lack of randomization and blinding.²⁰ Another study in which 45 patients were randomly assigned to either intradermal PRP, topical TCA 100%, or microneedling with topical PRP showed that all 3 groups had statistically significant improvement in the severity of their acne scars on the GBGS, with no differences between groups.²¹ Another prospective study evaluated the improvement of acne scars when microneedling was combined with PRP or VC.²² Twenty-seven out of 30 patients completed 4 sessions of microneedling and PRP on one side of the face and microneedling with VC on the contralateral side. Twenty-three patients demonstrated a one- to 2-grade reduction in scarring although one developed PIH and dropped out of the study. “Excellent” results (2-grade reduction) were more common with PRP compared to VC (18.5% vs 7%, $p < 0.05$) although “good” response rates (1-grade reduction) were similar. Improvement was seen in boxcar and rolling scars, but there was limited efficacy seen with ice pick scars.²²

The efficacy of glycolic acid (GA) combined with microneedling has also been studied. In one trial, 30 patients (FST III–V) with boxcar or rolling acne scars received either microneedling combined with GA or microneedling alone.²³ Outcomes were evaluated with the Echelle d’Evaluation Clinique des Cicatrices d’acne (ECCA) grading system.²³ Subjects treated with both microneedling and GA demonstrated a significantly greater decrease in ECCA score compared to microneedling alone (62% vs 31.33%). Several patients developed milia and transient hyperpigmentation.²³

Microneedling with fractional radiofrequency (MFR) has also been employed in the study of acne scars. This modified treatment modality creates radiofrequency thermal zones without epidermal injury, leading to dermal remodeling and new collagen deposition.²⁴ Chandrashekar and colleagues treated 31 patients (FST III–V) with Grade 3 to 4 atrophic acne scars with 4 MFR treatments.²⁴ After 3 months, 80.6% of patients showed improvement by 2 grades, and 19.4% showed improvement by 1 grade. Five out of 31 patients experienced transient PIH and 2 developed transient tram-trak marks.²⁴ Another case series looked at acne scarring in Asian patients (FST III–V).²⁵ Twenty-six patients had 3 treatments with MFR and the results were evaluated by 2 blinded dermatologists using the global improvement scale (GIS). Objective evaluation was obtained via an Ultraviolet-A camera to measure skin surface characteristics. After 1 month, skin surface roughness improved significantly. At the 6-month follow-up, the improvement was judged as “excellent” in 8%, “good” in 23%, “fair” in 36.5%, and “slightly improved” in 32.5%. Punched out and rolling acne scars responded better than ice pick and hypertrophic acne scars. Adverse effects included moderate pain, transient PIH for 1 month (4%), and scabbing for 2 to 7 days (46%).²⁵ A separate case series assessed 30 patients with acne scars and enlarged facial pores after 2 sessions of MFR.²⁶ Acne scars were graded by 2 dermatologists, and pore size was evaluated using the Investigator Global Assessment (IGA). Transepidermal water loss (TEWL), sebum production, and dermal density of the right cheek were measured. After 2 sessions, the

grade of the acne scars improved in 22 of the 30 patients (77.3%), was unchanged in 7 patients (23.3%), and worsened in 1 patient (3.3%). Enlarged pores improved in 21 patients (70%) and became aggravated in 2 patients (6.7%). While skin surface roughness and dermal density improved, TEWL and sebum measurements did not change. Adverse effects were mild and transient.²⁶

In another case series, microneedling was performed along with targeted, pinpoint scar treatment with an ablative carbon dioxide (CO₂) laser.²⁷ Sixty patients were randomly assigned to either laser or laser with PCI. Patients were assessed by 3 blinded observers using GBGS. There was a statistically significant improvement after treatment in both groups with no difference between the treatment groups.²⁷

Acne

Microneedling with fractional radiofrequency has also been studied in the treatment of acne vulgaris. Two prospective studies showed significant decreases in inflammatory acne count and suggested that MFR is safe and effective for the treatment of active acne.^{28,29} The first was a case series that examined 18 patients with FST IV and moderate-severe acne treated with 2 sessions of MFR.²⁸ Improvement was evaluated by 2 blinded dermatologists using GIS. Among the 18 patients treated, improvement was >75% in 2, 50% to 75% in 8, and 25% to 50% in 6 patients.²⁸ A second case series examined 25 patients with moderate to severe acne treated with MFR 3 times at monthly intervals.²⁹ Acne lesions were assessed by counting inflammatory and noninflammatory lesions, while sebum production was measured using sebumeter (C-K Electronics, Cologne, Germany). Inflammatory acne decreased significantly after every treatment and was reduced by 90.11% at 3-month follow-up. There was a statistically significant reduction at each time point in noninflammatory lesions and a mean decrease of 36.9% in sebum excretion at the 3-month follow-up. No dyspigmentation, burns, or scarring were noted.²⁹

However, one case series found that while MFR reduced sebum production, it did not improve acne

severity.³⁰ The study evaluated 20 patients (FST III–IV) with moderate to severe acne treated with one session of MFR. The authors found that at 2-week follow-up after one MFR treatment, casual sebum levels and sebum excretion rates were significantly reduced by 30% to 60% and 70% to 80%, respectively, and both remained significantly below baseline after 8 weeks. Acne lesion count and acne severity showed temporary improvement with maximum efficacy at Week 2, but returned to baseline by Week 8. Two patients developed pustular eruptions that self-resolved within a week. The authors hypothesized that the temporary improvement of acne was due to thermal injury of the sebaceous glands or hyperkeratotic plug disruption in the follicular infundibula.³⁰

Other Scars

Microneedling has been studied for the treatment of a variety of scars including burns, striae, and other atrophic scars.^{4,31–38} One retrospective study examined 480 patients who received microneedling treatment for fine wrinkles (Group I), acne or burn scars (Group II), and lax skin/striae (Group III).⁴ Patients were treated with vitamin A and C (VAC) for at least 1 month prior to microneedling treatment. Histologic examination of 20 patients showed a significant increase in collagen deposition 6 months post-operatively, the collagen exhibited a normal lattice design instead of the parallel bundle arrangement seen in scar tissue. Elastic fiber staining showed an increase in elastin at 6 months postoperatively. Further, epidermal thickening was observed and attributed to a 40% thickening of the stratum granulosum and normalization of rete ridges.⁴ Two patients developed herpes simplex infections, no additional AE were reported.⁴

Schwarz and Laaff studied microneedling in 11 patients with acne and other post-traumatic scars, with punch biopsies before and 6 to 8 weeks after microneedling. Ten patients completed the study and all were satisfied with the results and willing to undergo another treatment. Histologic examination revealed an increase in collagen, dermal thickness, and elastic fibers subepidermally, with no change in epidermal thickness. No AE were noted.³¹

One case series examined the effects of 3 to 4 microneedling sessions on patients with GBGS Grade 2 to 4 atrophic scars of various etiologies, including 32 patients with acne scars, 2 with postvaricella scars, 2 with post-traumatic scars, and 1 patient with post-herpetic scars.³² Thirty-four patients had a reduction in severity by 1 or 2 grades. Rolling and boxcar scars responded best, pitted scars showed moderate improvement, while deep tunnels and complicated scars had minimal response.³² The patient with post-herpetic scarring saw an improvement of 2 grades while the post-traumatic and postvaricella patients had 1-grade improvements.³² Another case study of a 15-year-old girl (FST V) with varicella scars who underwent 3 sessions of PCI showed significant improvement of her scarring.³³

Three studies have also noted significant improvement in patients with striae distensae.^{34–36} A case series of 22 female subjects with striae noted improved skin texture and skin tightening without dyspigmentation 6 months after a single microneedling treatment.³⁴ A second case series studied 16 patients (FST III–IV) with striae distensae treated with 3 sessions of microneedling.³⁵ Seven patients had 51% to 100% improvement, while the remaining 9 showed 1% to 50% improvement. Post-treatment biopsies showed epidermal thickening and increased collagen and elastic fibers. Adverse effects included transient pain, erythema, bleeding, and pruritus.³⁵ Lastly, a RCT of 30 patients with FST IV were treated with fractional CO₂ laser only, MFR, or a combination of the two.³⁶ Improvement was evaluated 6 months after treatment using a visual analog scale (VAS) ranging from 1 to 4. The mean VAS score in the laser only group was 2.4, 1.9 in the MFR group, and 3.6 in the combination group. Skin biopsies showed epidermal thickening and increased collagen in the combination group. However, these patients also had more AE, with 30% of patients developing PIH.³⁶

There is interest in the use of microneedling for hypertrophic scars, as microneedling has been shown to normalize the extracellular collagen-elastin matrix in the reticular dermis of burn patients.³⁷ In one prospective study, 16 patients with postburn scarring received one to 4 sessions of microneedling and topical

VAC. Statistically significant improvements were observed on both the Patient and Observer Scale Assessment Scales (POSAS, 27 vs 19) and Vancouver Scar Scale (VSS, 7.5 vs 4.8). In one case report, a 50-year-old Korean woman with a chin burn scar treated with 5 sessions of conventional ablative CO₂ laser followed by microneedling showed relaxation of the contracture and improvement in texture and color.³⁸ However, the combination of treatments in one patient renders it difficult to interpret the independent effect of each treatment modality.

Melasma and Melanosis

Microneedling has also been utilized in the management of melasma and melanosis. In one RCT involving 60 patients (FST IV–V) with moderate to severe melasma, treatment with tranexamic acid (TA) micro-injections was compared with microneedling followed by the application of topical TA.³⁹ After 3 treatments, a mean improvement of 38% was observed in the Melasma Area Severity Index (MASI) in patients treated with TA injections, compared to 44% improvement in patients who received topical TA and microneedling. The authors attribute the improved outcome to the enhanced delivery of TA through the pores created through the use of microneedling.³⁹ A split-face trial with 20 patients (FST III–V) with melasma examined the administration of depigmentation serum containing rucinol and sophora-alpha with and without microneedling to augment serum delivery.⁴⁰ Combination therapy improved MASI scores from baseline significantly more than serum alone (10.1 vs 7.1, $p < 0.05$).⁴⁰

Microneedling was reported to be effective for a 48-year-old male (FST V) with severe, idiopathic periorbital melanosis who underwent treatment with the DermaFrac device (Genesis Biosystems, Lewisville, TX), which employs PCI and a simultaneous infusion of anti-aging and lightening compounds.⁴¹ Physician global assessment revealed 50% to 75% and 75% to 90% improvement, after 4 and 12 sessions, respectively.⁴¹

Photodamage and Actinic Keratoses

Microneedling has been used to supplement photodynamic therapy (PDT) for the treatment of actinic keratoses (AK) and photodamage. Twenty-one

patients (FST II–III) were treated with microneedling prior to the application of aminolevulinic acid (ALA) and irradiation with 630 nm red light and broadband-pulsed light for the treatment of facial photoaging.⁴² Mean Global Photoaging score significantly decreased from 3.57 to 2.24 after 3 months and 2.05 after 6 months. Statistically significant reductions were also seen in the appearance of fine lines, sallowness, and roughness. The authors hypothesize that microneedling augments absorption and penetration of ALA.⁴²

In another study, 10 patients (FST I–III) were treated with PDT with methyl aminolevulinate (MAL) after either pretreatment curettage or microneedling for the treatment of AKs and photodamage.⁴³ At 30-day follow-up, improvements were comparable between groups in regard to global score for photodamage, roughness, sallowness, and mottled pigmentation. Only patients treated with microneedling demonstrated significant improvements in coarse wrinkles and erythema. Overall, AK clearance was 88.3%, without significant differences in clearance rates between groups. Adverse effects, including erythema, edema, and crusting, were more common in patients treated with microneedling and one patient in the microneedling group developed a bacterial infection.⁴³

Another uncontrolled study investigated the use of microneedling combined with topical MAL-based PDT for AK management in 12 organ-transplant recipients.⁴⁴ Patients underwent 3 biweekly treatments and demonstrated complete resolution of all lesions. No new AKs were detected at 4-month follow-up and 83% of patients remained free of relapse 9 months after final treatment.⁴⁴

Skin Rejuvenation

Percutaneous collagen induction has also demonstrated benefit for skin rejuvenation and improvement of rhytides. In one study, 10 female patients were treated with microneedling for upper lip rhytides.⁴⁵ Thirty weeks after the completion of 2 treatment sessions, patients demonstrated a mean 2.3-fold reduction in wrinkle severity using the Wrinkle Severity Rating Scale (WSRS). This result was confirmed by

a 33% reduction in skin irregularity demonstrated by silicon replicas. No prolonged AE were reported.⁴⁵

In another study, 8 patients underwent 2 microneedling sessions to treat aging neck skin.⁴⁶ After 8 months, 7 of the 8 participants demonstrated improvements on the WSRS and the GAIS. Skin replicas from baseline and final follow-up demonstrated an average reduction of 29% in skin irregularity. Ultrasound demonstrated an average reduction of 24% in rhytides depth and revealed that skin thickness increased an average of 0.45 mm after treatment.⁴⁶

A split-face trial studied the use of MFR with or without a “stem cell conditioned medium” of growth factors and cytokines for the purpose of skin rejuvenation in 15 female patients (FST III–IV).⁴⁷ Patients were treated with MFR alone on one side of the face and MFR plus stem cell medium on the contralateral side. After 3 treatment sessions, both sides showed improvements in hydration, erythema index, and skin roughness. Microneedling with fractional radio-frequency plus medium had a moderate benefit in overall appearance over MFR alone (2.06 vs 2.20). Histologic specimens demonstrated collagen and fibrillin-1 production.⁴⁷

Hyperhidrosis

It has been hypothesized that MFR, through thermal injury to sweat glands, may benefit patients with hyperhidrosis. In one prospective study, 20 patients underwent 2 treatments with MFR.⁴⁸ Statistically significant decreases in hyperhidrosis disease severity scale (HDSS) scores from a baseline of 3.3 to 1.5 and 1.8 were observed after 1 and 2 months, respectively. The starch–iodine reaction was also considerably reduced in 95% of the patients post-treatment.⁴⁸ Biopsies confirmed a decrease in the number and size of apocrine and eccrine glands 1 month after final treatment.⁴⁸

Alopecia

Research has been conducted on treating androgenetic alopecia with microneedling. It is hypothesized that PCI stimulates stem cells and induces growth factors, which are essential in the expression of hair growth

related genes.⁴⁹ One prospective study considered 100 men with androgenetic alopecia and randomized the patients to either microneedling with 5% minoxidil lotion or only minoxidil twice daily.⁴⁹ After 12 weeks of treatment, the hair count was significantly greater in 80% of patients treated with both microneedling and minoxidil, compared to no significant change in the minoxidil only group.⁴⁹ Microneedling has also shown promise in the treatment of alopecia areata. Two patients with alopecia areata treated with 3 sessions of microneedling followed by topical triamcinolone acetonide had excellent and durable hair growth over a 3-month follow-up period.⁵⁰

Drug Delivery

Microneedling is also used to enhance TDD through several methods including pore creation through the skin followed by topical drug application, drug-coated microneedle arrays, and direct drug injection through hollow microneedles.⁷ Animal studies confirm microneedling creates pores through the stratum corneum and, through delayed pore closure, allows for effective intradermal and transdermal drug delivery for a number of drugs including insulin and protein vaccines.^{51–53} Microneedling can also be synergistically combined with other procedures, such as iontophoresis, electroporation, and sonophoresis.⁵⁴

One prospective study examined the use of microneedling for the delivery of topical anesthetics.⁵⁵ A small patch on the forearm of 15 subjects was needled followed by application of lidocaine-prilocaine anesthetic, while on the other forearm the anesthetic was applied without needling. After 60 minutes, a 27-G needle was introduced and the VAS pain scores were compared. Microneedling prior to the topical anesthetic resulted in a significantly reduced VAS pain score compared to lidocaine-prilocaine alone (51.3 vs 20.1).⁵⁵

Adverse Effects

Microneedling is associated with a low rate of AE. Histologic examination taken 24 hours after therapy demonstrates an intact epidermis and no change in melanocyte number, resulting in limited downtime and minimal risk of dyspigmentation.⁵ Adverse effects

are rare and temporary, with transient postprocedure erythema being most common.⁶ Tram-trak markings are also rarely reported.⁸

One case study reported 2 sisters who developed systemic hypersensitivity reactions after microneedling, possibly to the needles themselves.⁵⁶ In another case series, 3 patients developed biopsy confirmed, foreign body-type facial granulomas after microneedling with topical VC.⁵⁷ In 2 patients, patch testing was reactive to VC. The authors propose that channels created by microneedling may facilitate the deposition of immunogenic particles into the dermis.⁵⁷

Conclusion

Over the past 20 years, the applications of microneedling in dermatology have grown drastically. The concept of subcision for scars has progressed to automated microneedling pens, MFR, and facilitation of TDD. This review highlights the encouraging results and limitations that have been reported with microneedling for a variety of conditions including scars, acne, melasma, photodamage, skin rejuvenation, hyperhidrosis, alopecia, and TDD. Current data show that microneedling provides the advantage of epidermal preservation while promoting production of dermal collagen and elastin. Overall, its efficacy, safety, and ease of use, make microneedling a favorable therapeutic alternative to consider. However, it should be noted that the majority of microneedling studies have been case series and small RCTs. Given that microneedling, similar to lasers and other noninvasive devices, is being used on an increasing basis by not only physicians but also by physician extenders, nurses, aestheticians, and even patients using at home devices, continued research on the safety and efficacy of microneedling is essential. In particular, there is a need for larger, double-blinded, RCTs, including subjects of all skin types in order to provide further insight and evidence-based data on the utility of this promising treatment modality.

References

- Fernandes D. Minimally invasive percutaneous collagen induction. *Oral Maxillofac Surg Clin North Am* 2005;17:51–63, vi.
- Camirand A, Doucet J. Needle dermabrasion. *Aesthet Plast Surg* 1997;21:48–51.
- Orentreich DS, Orentreich N. Subcutaneous incisionless (subcision) surgery for the correction of depressed scars and wrinkles. *Dermatol Surg* 1995;21:543–9.
- Aust MC, Fernandes D, Kolokythas P, Kaplan HM, et al. Percutaneous collagen induction therapy: an alternative treatment for scars, wrinkles, and skin laxity. *Plast Reconstr Surg* 2008;121:1421–9.
- Aust MC, Reimers K, Repenning C, Stahl F, et al. Percutaneous collagen induction: minimally invasive skin rejuvenation without risk of hyperpigmentation—fact or fiction? *Plast Reconstr Surg* 2008;122:1553–63.
- Doddaballapur S. Microneedling with dermaroller. *J Cutan Aesthet Surg* 2009;2:110–1.
- Vandervoort J, Ludwig A. Microneedles for transdermal drug delivery: a minireview. *Front Biosci* 2008;13:1711–5.
- Harris Adam NC, Murrell D. Skin needling as a treatment for acne scarring: an up-to-date review of the literature. *Int J Women Dermatol* 2015;1:77–81.
- Alam M, Han S, Pongpruthiphan M, Wareeporn D, et al. Efficacy of a needling device for the treatment of acne scars: a randomized clinical trial. *JAMA Dermatol* 2014;150:844–9.
- Fabbrocini G, De Vita V, Monfrecola A, De Padova MP, et al. Percutaneous collagen induction: an effective and safe treatment for post-acne scarring in different skin phototypes. *J Dermatolog Treat* 2014;25:147–52.
- Fabbrocini G, Fardella N, Monfrecola A, Proietti I, et al. Acne scarring treatment using skin needling. *Clin Exp Dermatol* 2009;34:874–9.
- Dogra S, Yadav S, Sarangal R. Microneedling for acne scars in Asian skin type: an effective low cost treatment modality. *J Cosmet Dermatol* 2014;13:180–7.
- Pahwa M, Pahwa P, Zaheer A. “Tram track effect” after treatment of acne scars using a microneedling device. *Dermatol Surg* 2012;38(7 Pt 1):1107–8.
- Hassan R. Comparison of efficacy of micro needling for the treatment of acne scars in Asian skin with and without subcision. *J Turk Acad Dermatol* 2015;9:159–66.
- Gadkari R, Nayak C. A split-face comparative study to evaluate efficacy of combined subcision and dermaroller against combined subcision and cryoroller in treatment of acne scars. *J Cosmet Dermatol* 2014;13:38–43.
- Leheta T, El Tawdy A, Abdel Hay R, Farid S. Percutaneous collagen induction versus full-concentration trichloroacetic acid in the treatment of atrophic acne scars. *Dermatol Surg* 2011;37:207–16.
- Garg S, Baveja S. Combination therapy in the management of atrophic acne scars. *J Cutan Aesthet Surg* 2014;7:18–23.
- Leheta TM, Abdel Hay RM, El Garem YF. Deep peeling using phenol versus percutaneous collagen induction combined with trichloroacetic acid 20% in atrophic post-acne scars: a randomized controlled trial. *J Dermatolog Treat* 2014;25:130–6.
- Leheta TM, Abdel Hay RM, Hegazy RA, El Garem YF. Do combined alternating sessions of 1540 nm nonablative fractional laser and percutaneous collagen induction with trichloroacetic acid 20% show better results than each individual modality in the treatment of atrophic acne scars? A randomized controlled trial. *J Dermatolog Treat* 2014;25:137–41.
- Fabbrocini G, De Vita V, Pastore F, Panariello L, et al. Combined use of skin needling and platelet-rich plasma in acne scarring treatment. *Cosmet Dermatol* 2011;24:177–83.
- Nofal E, Helmy A, Nofal A, Alakad R, et al. Platelet-rich plasma versus CROSS technique with 100% trichloroacetic acid versus combined skin needling and platelet rich plasma in the treatment of atrophic acne scars: a comparative study. *Dermatol Surg* 2014;40:864–73.
- Chawla S. Split face comparative study of microneedling with PRP versus microneedling with vitamin C in treating atrophic post acne scars. *J Cutan Aesthet Surg* 2014;7:209–12.

23. Sharad J. Combination of microneedling and glycolic acid peels for the treatment of acne scars in dark skin. *J Cosmet Dermatol* 2011;10:317–23.
24. Chandrashekar BS, Sriram R, Mysore R, Bhaskar S, et al. Evaluation of microneedling fractional radiofrequency device for treatment of acne scars. *J Cutan Aesthet Surg* 2014;7:93–7.
25. Vejjabhinanta V, Wanitphakdeedecha R, Limtanyakul P, Manuskitti W. The efficacy in treatment of facial atrophic acne scars in Asians with a fractional radiofrequency microneedle system. *J Eur Acad Dermatol Venereol* 2014;28:1219–25.
26. Cho SI, Chung BY, Choi MG, Baek JH, et al. Evaluation of the clinical efficacy of fractional radiofrequency microneedle treatment in acne scars and large facial pores. *Dermatol Surg* 2012;38(7 Pt 1):1017–24.
27. Mohammed G. Randomized clinical trial of CO₂ laser pinpoint irradiation technique with/without needling for ice pick acne scars. *J Cosmet Laser Ther* 2013;15:177–82.
28. Lee SJ, Goo JW, Shin J, Chung WS, et al. Use of fractionated microneedle radiofrequency for the treatment of inflammatory acne vulgaris in 18 Korean patients. *Dermatol Surg* 2012;38:400–5.
29. Kim ST, Lee KH, Sim HJ, Suh KS, et al. Treatment of acne vulgaris with fractional radiofrequency microneedling. *J Dermatol* 2014;41:586–91.
30. Lee KR, Lee EG, Lee HJ, Yoon MS. Assessment of treatment efficacy and sebostimulatory effect of fractional radiofrequency microneedle on acne vulgaris. *Lasers Surg Med* 2013;45:639–47.
31. Schwarz M, Laaff H. A prospective controlled assessment of microneedling with the Dermaroller device. *Plast Reconstr Surg* 2011;127:146e–148e.
32. Majid I. Microneedling therapy in atrophic facial scars: an objective assessment. *J Cutan Aesthet Surg* 2009;2:26–30.
33. Costa IM, Costa MC. Microneedling for varicella scars in a dark-skinned teenager. *Dermatol Surg* 2014;40:333–4.
34. Aust MC, Knobloch K, Vogt PM. Percutaneous collagen induction therapy as a novel therapeutic option for Striae distensae. *Plast Reconstr Surg* 2010;126:219e–220e.
35. Park KY, Kim HK, Kim SE, Kim BJ, et al. Treatment of striae distensae using needling therapy: a pilot study. *Dermatol Surg* 2012;38:1823–8.
36. Ryu HW, Kim SA, Jung HR, Ryoo YW, et al. Clinical improvement of striae distensae in Korean patients using a combination of fractionated microneedle radiofrequency and fractional carbon dioxide laser. *Dermatol Surg* 2013;39:1452–8.
37. Aust MC, Knobloch K, Reimers K, Redeker J, et al. Percutaneous collagen induction therapy: an alternative treatment for burn scars. *Burns* 2010;36:836–43.
38. Cho SB, Lee SJ, Kang JM, Kim YK, et al. The treatment of burn scar-induced contracture with the pinhole method and collagen induction therapy: a case report. *J Eur Acad Dermatol Venereol* 2008;22:513–4.
39. Budamakuntla L, Loganathan E, Suresh DH, Shanmugam S, et al. A randomised, open-label, comparative study of tranexamic acid microinjections and tranexamic acid with microneedling in patients with melasma. *J Cutan Aesthet Surg* 2013;6:139–43.
40. Fabbrocini G, De Vita V, Fardella N, Pastore F, et al. Skin needling to enhance depigmenting serum penetration in the treatment of melasma. *Plast Surg Int* 2011;2011:158241.
41. Sahni K, Kassir M. Dermafrac: an innovative new treatment for periorbital melanosis in a dark-skinned male patient. *J Cutan Aesthet Surg* 2013;6:158–60.
42. Clementoni MT, B-Roscher M, Munavalli GS. Photodynamic photorejuvenation of the face with a combination of microneedling, red light, and broadband pulsed light. *Lasers Surg Med* 2010;42:150–9.
43. Torezan L, Chaves Y, Niwa A, Sanches JA Jr, et al. A pilot split-face study comparing conventional methyl aminolevulinate-photodynamic therapy (PDT) with microneedling-assisted PDT on actinically damaged skin. *Dermatol Surg* 2013;39:1197–201.
44. Bencini PL, Galimberti MG, Pellacani G, Longo C. Application of photodynamic therapy combined with pre-illumination microneedling in the treatment of actinic keratosis in organ transplant recipients. *Br J Dermatol* 2012;167:1193–4.
45. Fabbrocini G, De Vita V, Pastore F, Annunziata MC, et al. Collagen induction therapy for the treatment of upper lip wrinkles. *J Dermatol Treat* 2012;23:144–52.
46. Fabbrocini G, De Vita V, Di Costanzo L, Pastore F, et al. Skin needling in the treatment of the aging neck. *Skinmed* 2011;9:347–51.
47. Seo KY, Kim DH, Lee SE, Yoon MS, et al. Skin rejuvenation by microneedle fractional radiofrequency and a human stem cell conditioned medium in Asian skin: a randomized controlled investigator blinded split-face study. *J Cosmet Laser Ther* 2013;15:25–33.
48. Kim M, Shin JY, Lee J, Kim JY, et al. Efficacy of fractional microneedle radiofrequency device in the treatment of primary axillary hyperhidrosis: a pilot study. *Dermatology* 2013;227:243–9.
49. Dhurat R, Sukesh M, Avhad G, Dandale A, et al. A randomized evaluator blinded study of effect of microneedling in androgenetic alopecia: a pilot study. *Int J Trichology* 2013;5:6–11.
50. Chandrashekar B, Yepuri V, Mysore V. Alopecia areata-successful outcome with microneedling and triamcinolone acetonide. *J Cutan Aesthet Surg* 2014;7:63–4.
51. Li K, Yoo KH, Byun HJ, Lim YY, et al. The microneedle roller is an effective device for enhancing transdermal drug delivery. *Int J Dermatol* 2012;51:1137–9.
52. Prausnitz MR. Microneedles for transdermal drug delivery. *Adv Drug Deliv Rev* 2004;56:581–7.
53. Kaushik S, Hord AH, Denson DD, McAllister DV, et al. Lack of pain associated with microfabricated microneedles. *Anesth Analg* 2001;92:502–4.
54. Kim YC, Park JH, Prausnitz MR. Microneedles for drug and vaccine delivery. *Adv Drug Deliv Rev* 2012;64:1547–68.
55. Fabbrocini G, De Vita V, Izzo R, Monfrecola G. The use of skin needling for the delivery of a eutectic mixture of local anesthetics. *G Ital Dermatol Venereol* 2014;149:581–5.
56. Pratsou P, Gach J. Severe systemic reaction associated with skin microneedling therapy in 2 sisters: a previously unrecognized potential for complications?. *J Am Acad Dermatol* 2013;68:AB219.
57. Soltani-Arabshahi R, Wong JW, Duffy KL, Powell DL. Facial allergic granulomatous reaction and systemic hypersensitivity associated with microneedle therapy for skin rejuvenation. *JAMA Dermatol* 2014;150:68–72.

Address correspondence and reprint requests to: Nada Elbuluk, MD, MSc, The Ronald O. Perelman Department of Dermatology, New York University School of Medicine, 240 East 38th Street 11th floor, New York, NY 10016, or e-mail: Nada.Elbuluk@nyumc.org